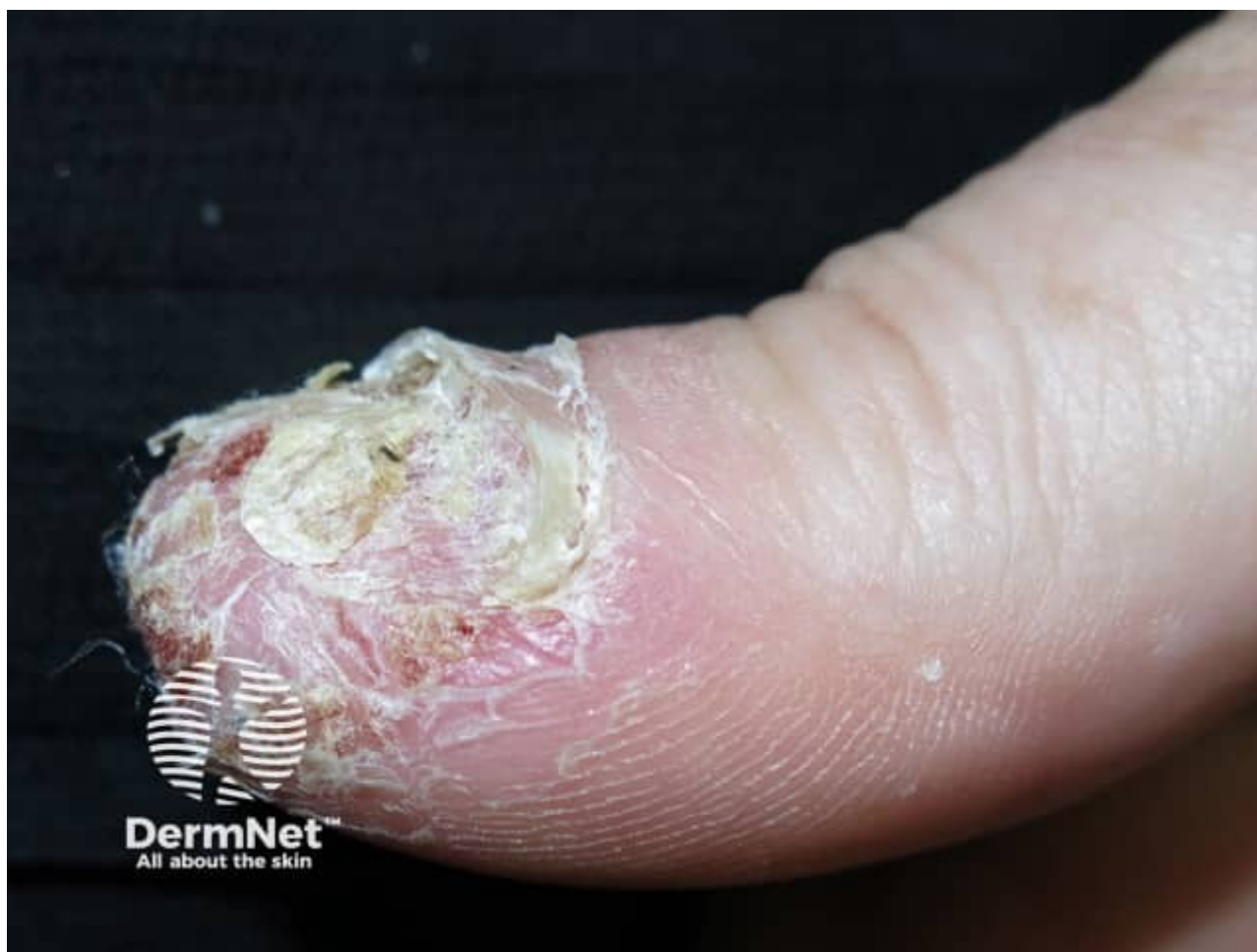

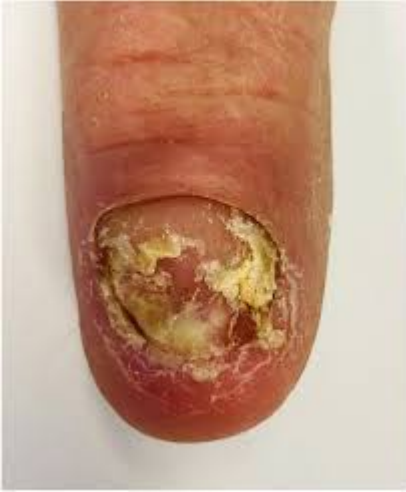Acrodermatitis Continua of Hallopeau (ACH)

Acrodermatitis Continua of Hallopeau (ACH)

Definition and Overview



<https://www.bmj.com/content/bmj/380/bmj-2022-073447/F1.large.jpg>



4

- A rare, chronic, and **sterile pustular skin disorder** affecting the **fingers or toes**.
 - Often involves the **nail beds**, leading to **deformity or destruction of the distal phalanx**.
 - Considered a **localized variant of pustular psoriasis** with unique features and progression.
-

Epidemiology

- **Rarity:** Uncommon disorder, mostly sporadic cases.
- **Age of Onset:** Can occur at any age, more common in **adults and elderly**.
- **Gender Predominance:** Slight **female predominance**.

Triggering Factors:

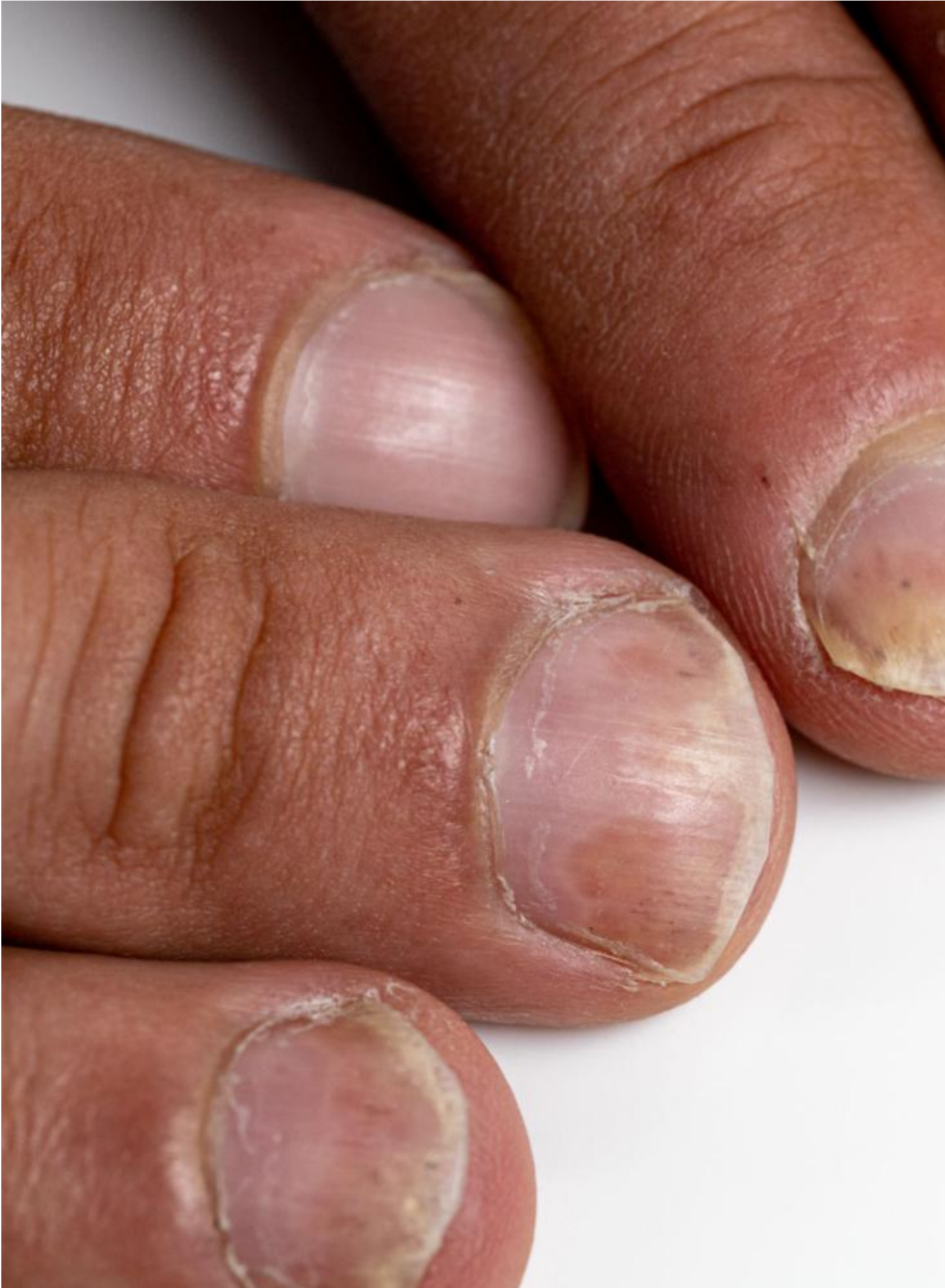- Minor trauma, infections, external irritants.
 - May be exacerbated by **systemic corticosteroids**.
-

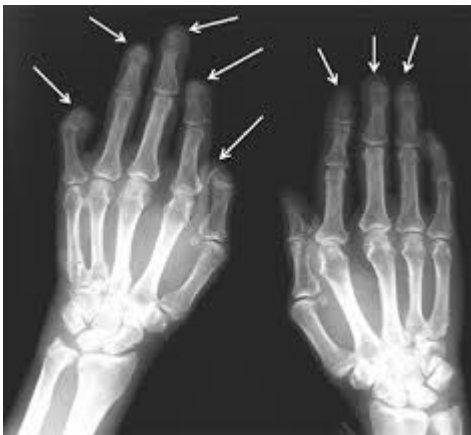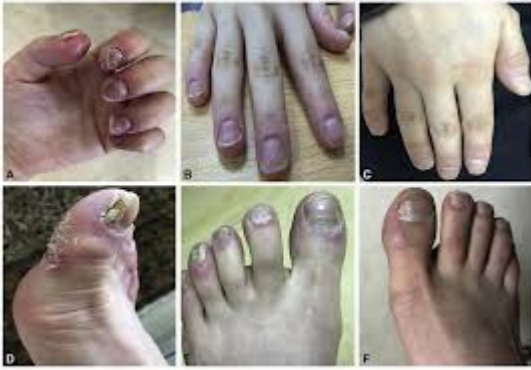Clinical Features

Initial Presentation

- **Primary Lesion:**
 - Erythematous, scaly patches or plaques.
 - **Sterile pustules** at tips of fingers (rarely toes).
 - Commonly involves **one or two digits**, especially the thumb.
 - **Symptoms:**
 - Pustules rupture ? **crusts or erosions**.
 - Pain, tenderness, discomfort.
-

Progression





4

- **Nail Involvement:**

- Nail folds, bed, matrix involvement ?
 - Nail dystrophy
 - Complete loss of nail plates (**onycholysis**)
- Chronic disease ? **permanent nail destruction**

- **Bone and Joint Changes:**

- **Osteolysis** (loss of distal phalanx)
- Joint stiffness or deformity (resembles psoriatic arthritis)

- **Spread:**

- Proximal extension along digit
- May involve multiple digits

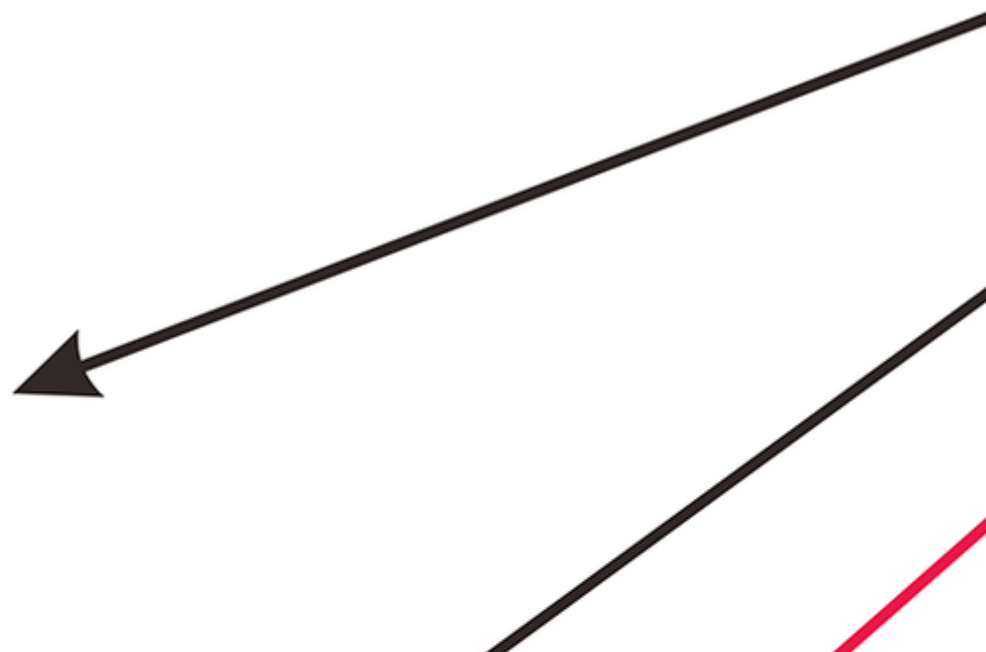
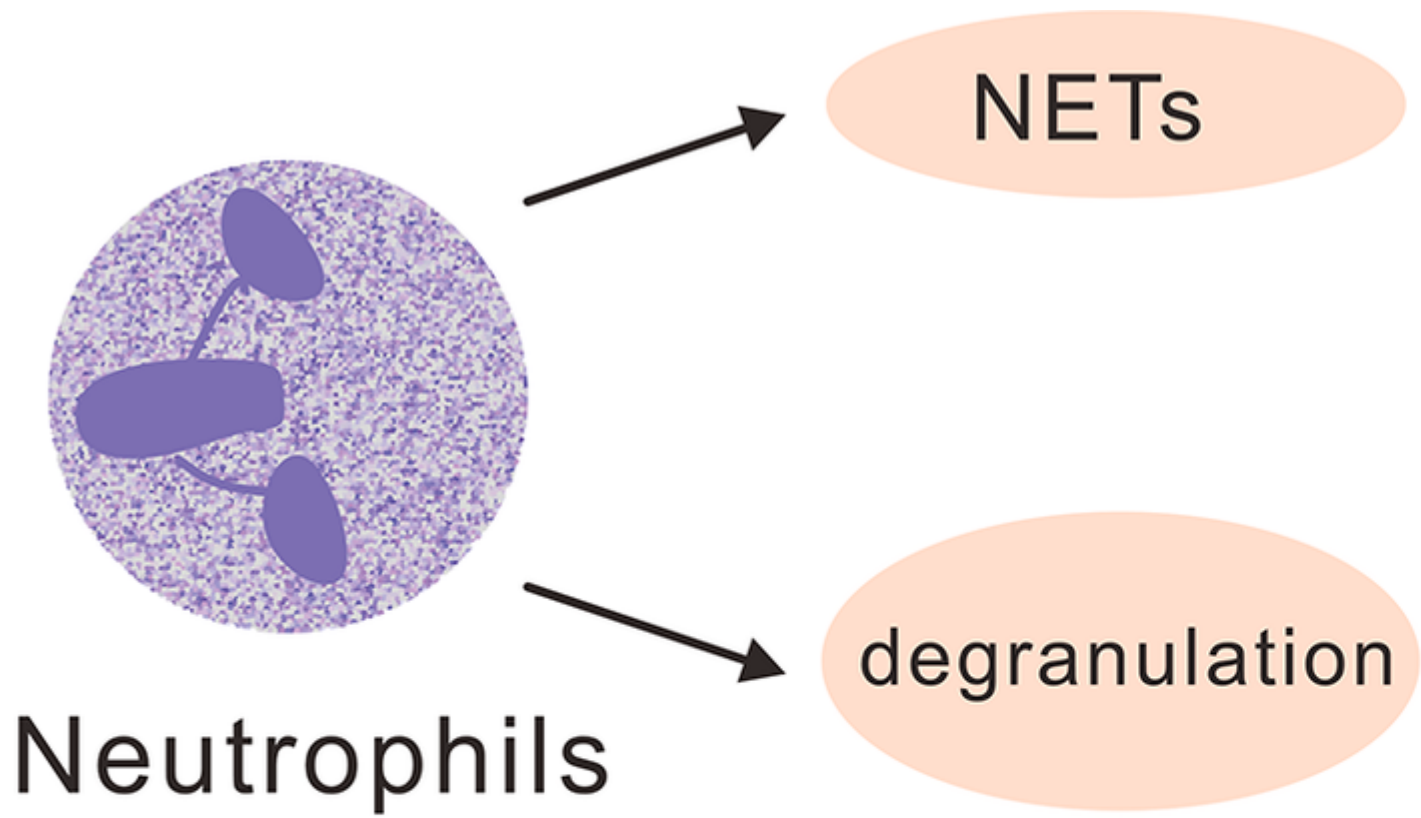
- **Generalization:**

- Can progress to **generalized pustular psoriasis** (life-threatening)
-

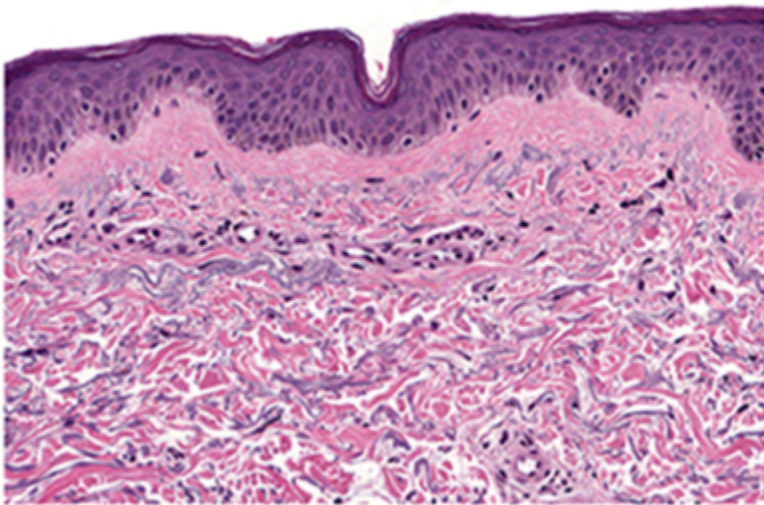
Morphological Patterns

- **Localized Pattern:** Limited to one/few digits, chronic course.
 - **Diffuse Pattern:** Progressive spread with generalized pustulation.
-

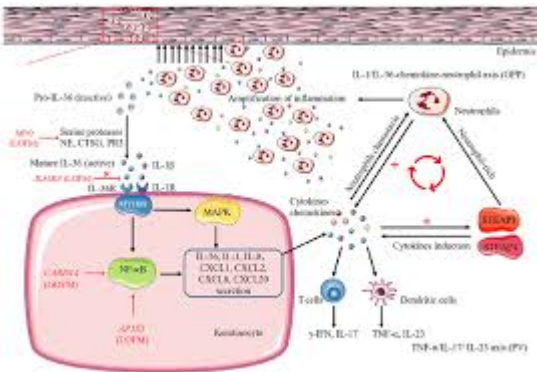
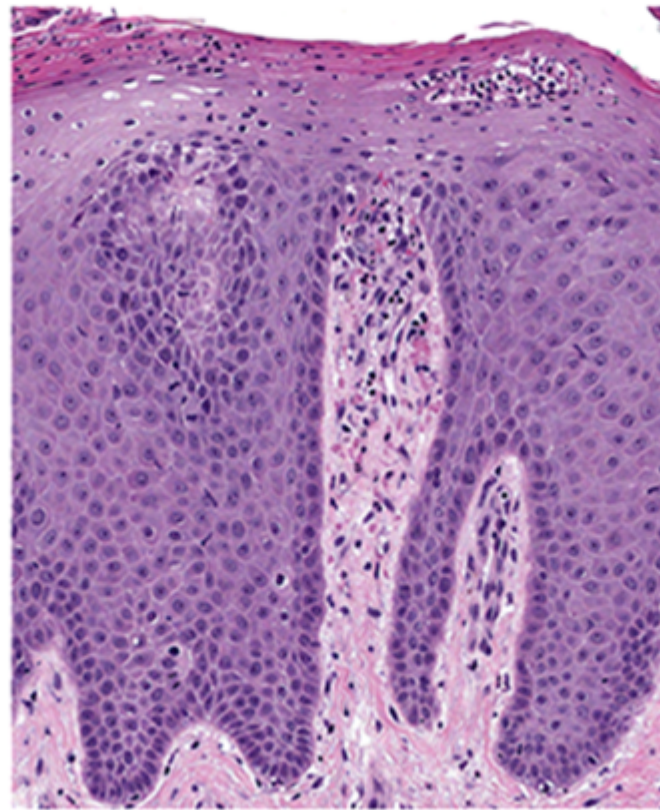
Pathogenesis



A Normal skin



B Pustular Psoriasis



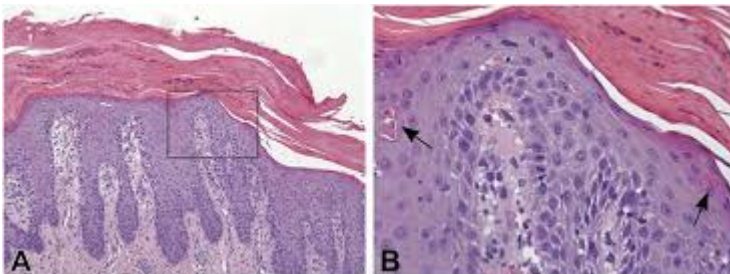
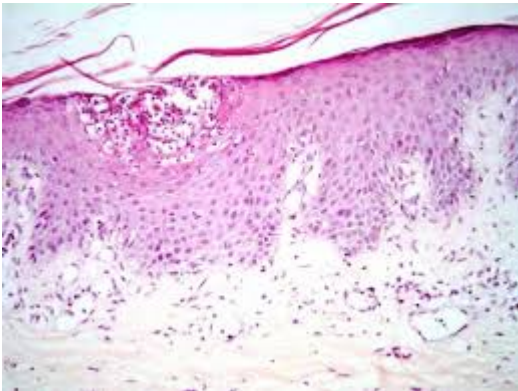
4

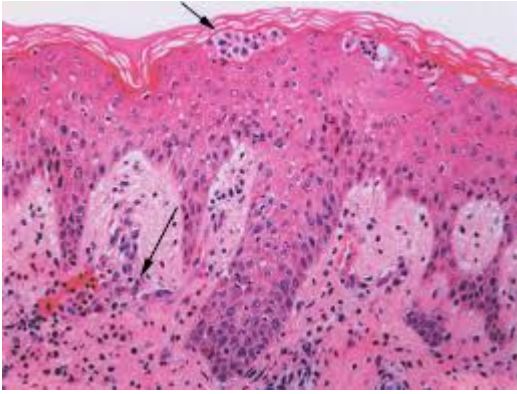
- **Autoimmune Nature:**

- Dysregulation of innate immunity

- Neutrophil activation
- Elevated **IL-36** cytokines
- **Genetic Associations:**
 - Mutations in **IL36RN**
 - Mutations in **API33**
- **Triggers:**
 - Trauma, stress, infections, irritants

Histopathology





4

- **Subcorneal neutrophilic pustules** (hallmark).
- **Spongiform pustules**, parakeratosis, epidermal thinning.
- **Chronic cases:**
 - Epidermal atrophy
 - Fibrosis
 - Dermal inflammation
- **Key feature:** Absence of infectious agents in pustules.

Investigations

- **Clinical diagnosis** based on characteristic lesions.
- **Laboratory tests:**
 - Rule out bacterial/fungal infections (sterile pustules).
 - **Genetic testing** (IL36RN, AP1S3).

- **Imaging:**

- X-ray ? detect **osteolysis or deformities**.

- **Histology:**

- Confirms neutrophilic pustules.
-

Differential Diagnosis

- **Infectious:**

- Herpetic whitlow
- Candidiasis

- **Inflammatory:**

- Psoriatic arthritis
- Onychomycosis
- Parakeratosis pustulosa

- **Traumatic:**

- Traumatic onycholysis
 - Contact dermatitis
-

Disease Course

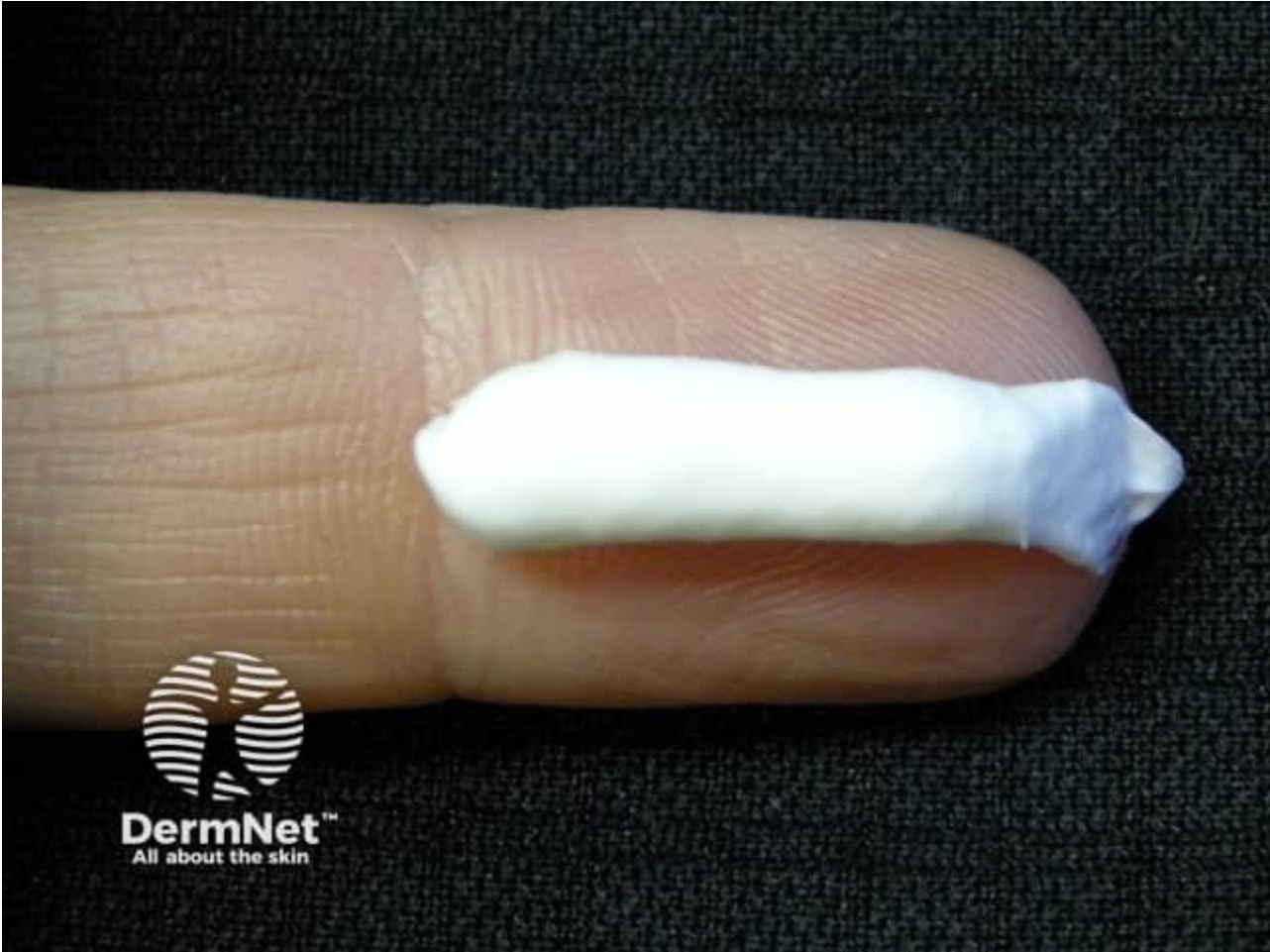- **Chronic and relapsing.**
- Persists for months to years.

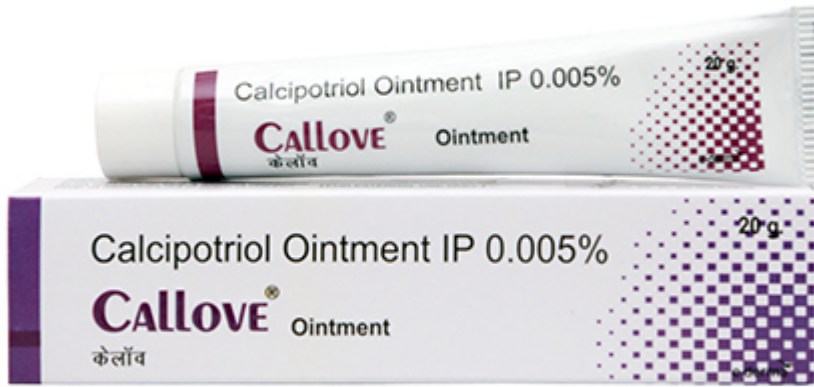Complications:

- Nail destruction
 - Severe deformity and disability
 - **Spontaneous remission:** Rare
-


Management and Treatment

Local Treatments





Tacrolimus Ointment (T



- Effective for Eczema
- Non-Steroidal
- Suitable for Adults & Children
- Reduces Inflammation
- Relieves Itching



SCOTDERMA
Committed to Dermatology

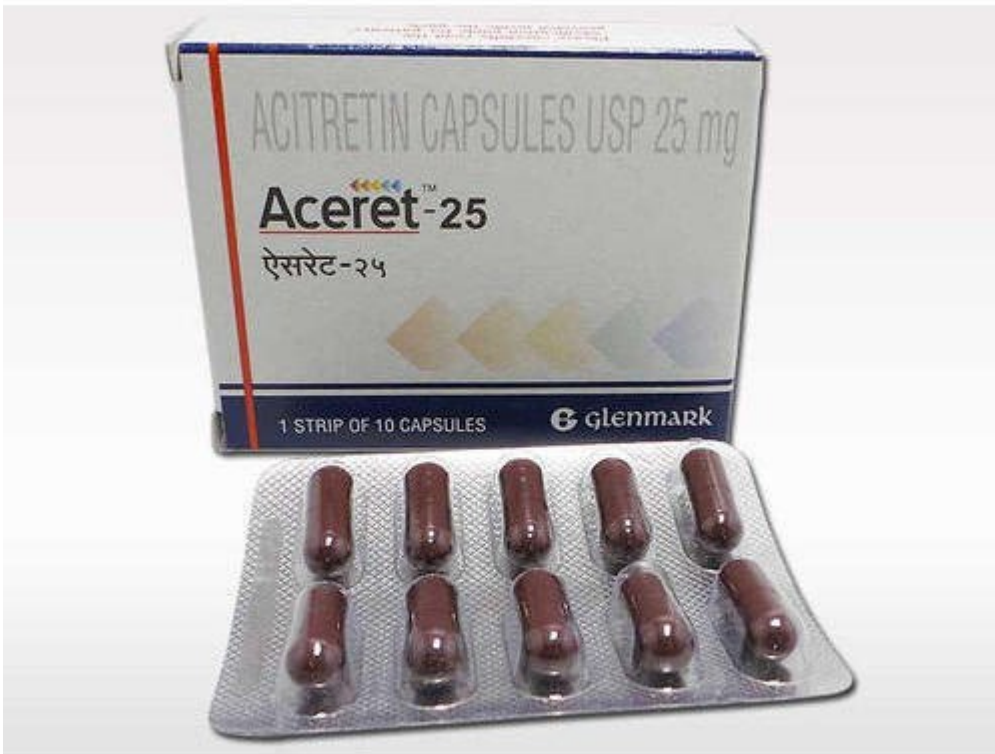 www.scotderma.com

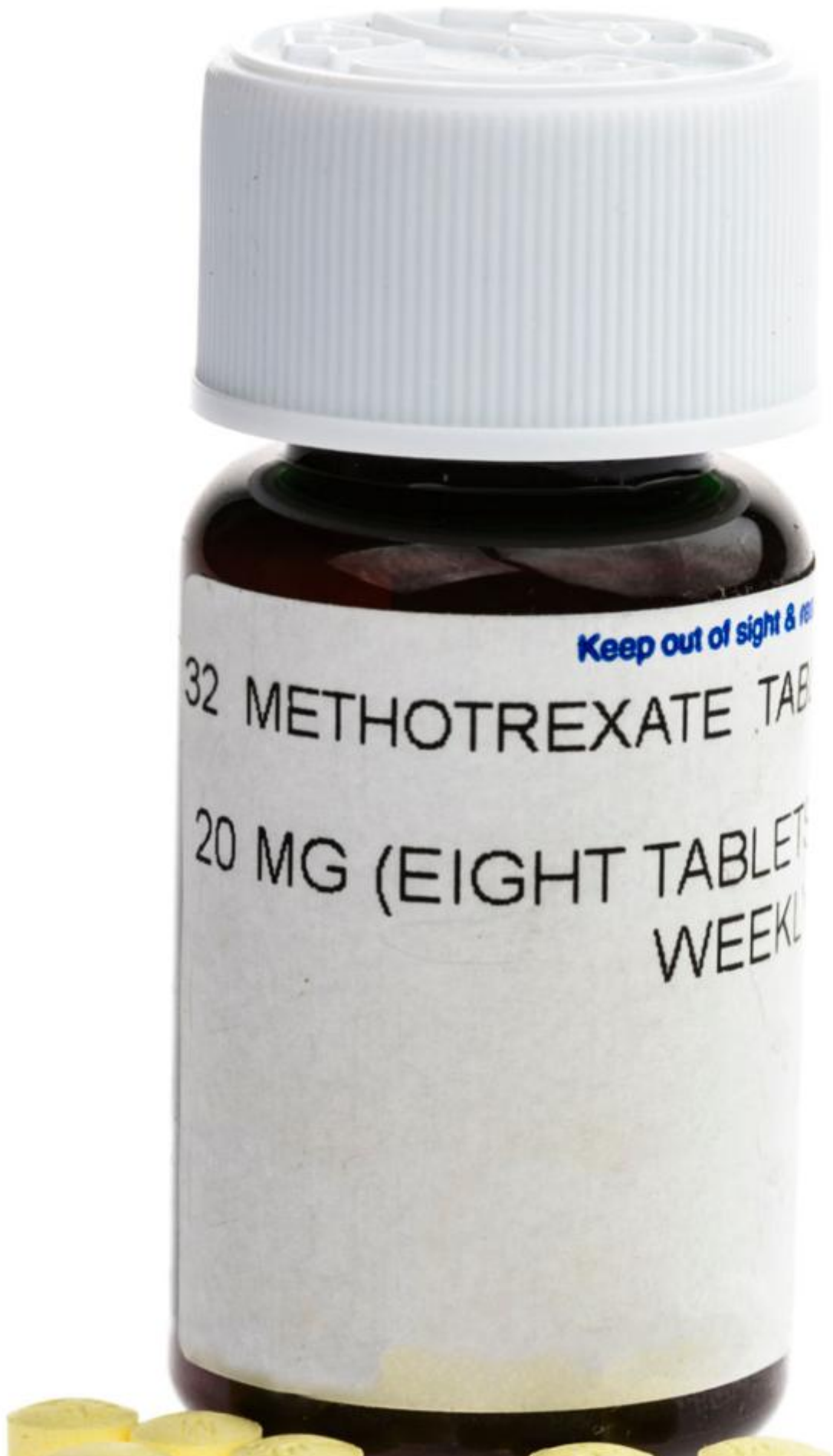 +91987594503

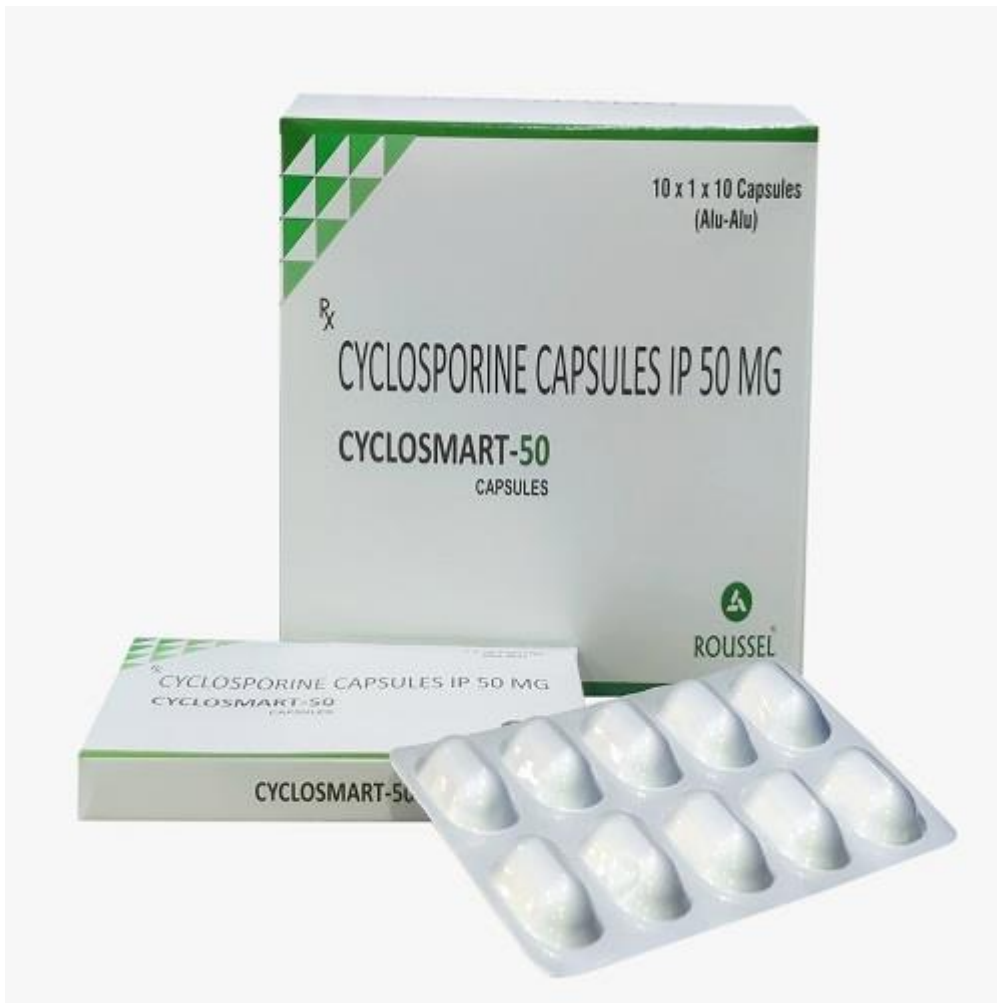4

- **Topical corticosteroids** (with occlusion).
- **Vitamin D analogues** (calcipotriol).
- **Topical tacrolimus.**

Systemic Treatments







5

- **First-line:**

- Acitretin (0.3–0.5 mg/kg/day)
- Methotrexate
- Ciclosporin

- **Second-line:**

- **Biologics:**

- TNF- α inhibitors (Infliximab, Adalimumab)
 - IL-17 inhibitors (Secukinumab)
 - IL-23 inhibitors (Ustekinumab)
 - **IL-1 blockade:** Anakinra
-

Combination Therapy

- Acitretin + PUVA
 - Methotrexate + biologics
-

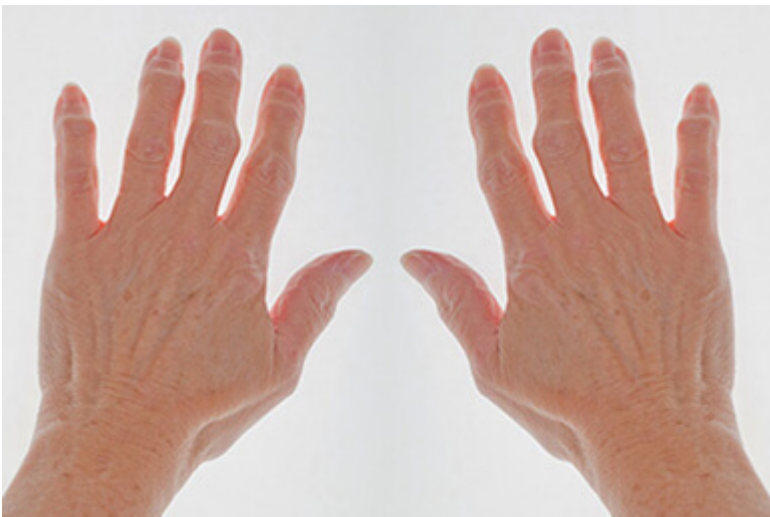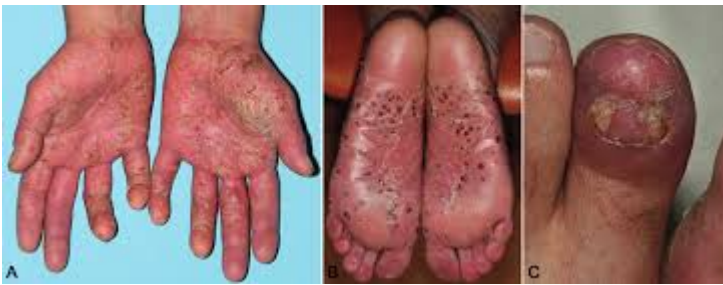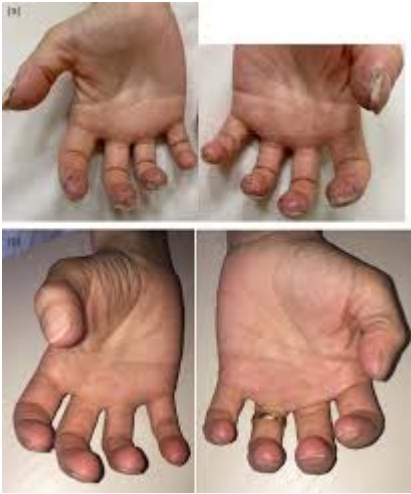Supportive Care

- Protect digits from trauma.
 - Treat secondary infections if present.
-

Prognosis

- **Localized ACH:**
 - Treatable but relapsing
 - Functional impairment possible
- **Generalized ACH:**
 - Requires aggressive therapy
 - High morbidity

Key Points



- Early diagnosis prevents **nail loss and bone deformities**.
- **IL36RN mutation testing** helps guide biologic therapy.
- Long-term remission often requires **multimodal treatment**